

Longitudinal tear of the biceps brachii from peripheral intravenous catheter infiltration

Ameet S. Nagpal¹
Jon A. Benfield²
Rochelle T. Dy³

¹ Department of Anesthesiology, University of Texas Health Science Center at San Antonio, USA

² Department of Physical Medicine & Rehabilitation, University of Texas Health Science Center at San Antonio, USA

³ Department of Physical Medicine & Rehabilitation, Texas Childrens Hospital, Baylor College of Medicine, Houston, USA

Corresponding author:

Jon A. Benfield

Department of Physical Medicine & Rehabilitation, University of Texas Health Science Center at San Antonio 7703 Floyd Curl Dr.

78240 San Antonio, USA

E-mail: benfield@uthscsa.edu

Summary

Background: although peripheral intravenous catheter (PIV) infiltration is a frequent hospital occurrence, muscle rupture is a previously unknown complication of line infiltration. We present the case of a 21-year-old male with a history of cystic fibrosis, bilateral lung transplant, and chronic corticosteroid use, with longitudinal tear of the biceps brachii muscle as a complication of PIV infiltration.

Methods: case report describing a unique case of a longitudinal tear of the biceps brachii.

Results: magnetic resonance imaging revealed longitudinal tear of the biceps brachii with sparing of the proximal and distal tendons. Nerve conduction studies and electromyography revealed bicipital denervation, most likely due to mechanical compression.

Conclusion: we hypothesize that the patient's chronic corticosteroid use predisposed him to muscle injury, as did basilic vein thrombosis caused by PIV infiltration, and this combination of factors led to bicipital rupture. To our knowledge, this is also the first case report to document longitudinal tear of the biceps brachii with sparing of the distal and proximal tendinous insertions of the muscle.

KEY WORDS: biceps, rupture, tendon, venous thrombosis.

Case Report

Background

A 21-year-old male with a history of cystic fibrosis and lung transplant in 2007, on chronic prednisone and tacrolimus, presented to the hospital with shortness of breath in March 2011. The patient was admitted to an intensive care unit and intubated, and a peripheral intravenous catheter (PIV) was placed in the right antebrachial fossa. The patient had diffuse swelling of the right upper extremity consistent with PIV infiltration that began 5 days later, and the PIV was moved to the opposite limb. This swelling occurred acutely over the course of a few hours. The patient was extubated 2 days later (hospital day 7), the patient was noted to have diffuse right upper limb pain and inability to perform elbow flexion. He also described anesthesia and paresthesias over the dorsum and palmar aspects of the first two digits as well as the thenar eminence and lateral forearm.

As the patient's swelling subsided over the two to three days following extubation, pain became localized to the medial biceps in the middle third of the muscle belly. Pain was reproducible with active flexion of the right elbow (which the patient was only able to perform up to 15 degrees), passive flexion of the right elbow, and palpation of the area. There was also bruising noted in the area of pain and tenderness, with no history of trauma. In addition to the noted weakness of elbow flexion, the patient had weakness of elbow supination (2/5 strength), though he was noted to have full active range of motion. Ultrasonography with Doppler of the right upper extremity was performed two days after swelling began which showed no evidence of venous occlusion.

One week after our initial consultation of the patient (week 3 of the patient's hospitalization), the patient's pain and weakness had not improved, though swelling had fully resolved. At this time, a repeat ultrasound with Doppler was performed which demonstrated an occluding thrombus in the most distal 6 cm of the basilic vein, which was not seen on the prior ultrasound. Concomitantly, magnetic resonance imaging of the right arm showed a longitudinal region of increased T2 and increased T1 signal tracking along the medial aspect of the biceps muscle belly and within the interspace between the biceps tendons consistent with an intramuscular hematoma along a longitudinal tear in the biceps muscle (Figs. 1, 2). Distal and proximal biceps tendons were spared. The

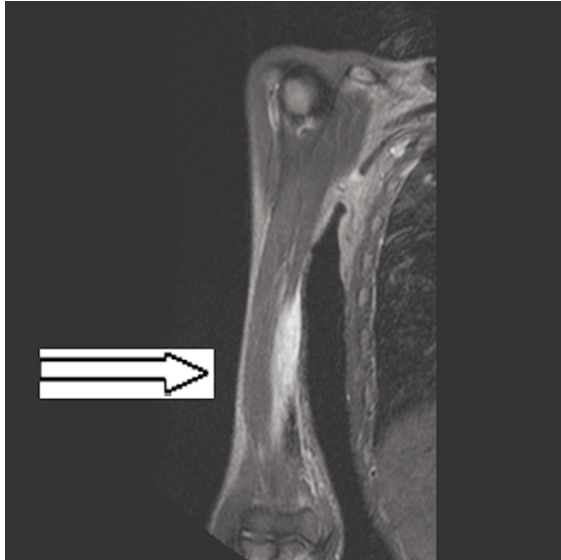

Figure 1. T1 IRTSE coronal magnetic resonance image showing biceps brachii tear and hematoma.

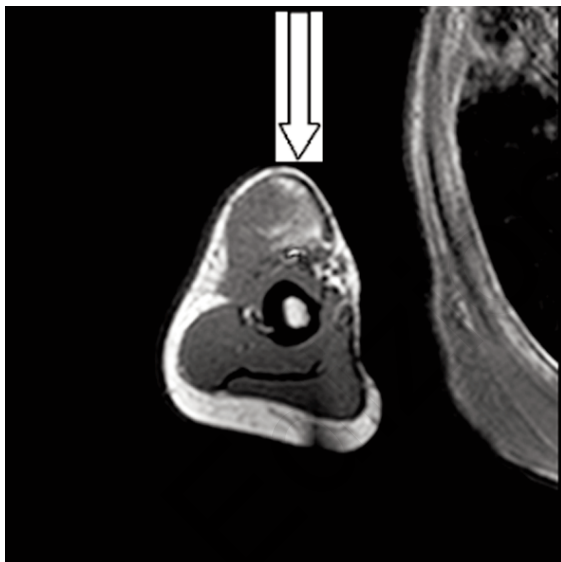


Figure 2. T1 axial coronal magnetic resonance image showing biceps brachii tear and hematoma.

patient does not have a history of bleeding diathesis or any other medical history beyond what has been described to explain any of his findings. Conservative management of the muscle tear with physical therapy was initiated and the patient was discharged home at the beginning of hospital week 4.

Results

Six weeks after discharge, the patient returned to our clinic for his follow-up visit. At this time, he continued to have decreased sensation over the lateral aspect

of the forearm, in the same distribution as previously reported. His strength had improved to 4/5 in right elbow supination and flexion. Electromyography and nerve conduction studies were performed which demonstrated denervation potentials in the right biceps brachii but with continued clinical improvement.

Methods

A literature review was conducted using PubMed and the above key words. To our knowledge, there are no known case reports describing muscle strain, rupture, or tear secondary to PIV infiltration. Additionally, we are unaware of any case reports describing longitudinal biceps brachii tear with sparing of the distal and proximal tendons. Longitudinal biceps tears are usually associated with rotator cuff lesions and are generally degenerative, chronic processes accompanied by proximal biceps tendon ruptures¹. Therefore, this case of an acute cause of longitudinal biceps tear is most unusual. Additionally, this case report and literature overview was conducted in accordance with international standards and ethical standards².

Discussion

The most common etiologies of biceps ruptures are due to contiguous muscle tears from proximal or distal tendon ruptures. As noted above, proximal tendon ruptures are often related to degenerative disease of the rotator cuff. This is anatomically correct, as the proximal short head of the biceps originates from the coracoid process and the long head originates at the supraglenoid tubercle. This predisposes the long head of the biceps to injury associated with rotator cuff pathology. The insertion of this muscle is at the ulnar portion of the antebrachial fascia and the radial tuberosity³. The radial tuberosity is the site of distal biceps tendon rupture, which is less common and tends to occur acutely during eccentric muscle contraction, with associated hematoma formation^{1, 4}. Operative treatment is preferred in the acute setting while conservative management tends to garner favor in the chronic setting¹.

Though this patient was on chronic immunosuppressive therapy, tacrolimus has never been shown to cause abnormalities in muscle. The patient was also on chronic mid-range dosing of prednisone (30 milligrams twice daily) which has been associated with many musculoskeletal disease states, including steroid myopathy, tendon rupture, and generalized muscle weakness⁵. It can be inferred that the patient's chronic use of corticosteroids may have predisposed him to the muscle tear that occurred. We hypothesize that this occurred when the PIV infiltrated, which resulted in basilic vein thrombus formation, leading to mechanical compression and stretch on muscle fibers already weakened by chronic prednisone use. While we appreciate that the hypothesized mechanism of injury is based upon conjecture, we feel that this is the most plausible explanation of

the patient's biceps tear. Other conceivable explanations include eccentric contraction of the biceps, trauma to the area that may have occurred during a transfer or turn while the patient was intubated and sedated, compartment syndrome from acute edema leading to neuropathy and muscular tear, and hematoma formation due to the infiltration of the PIV which has been misinterpreted as an intramuscular rupture. We feel that this truly was an intramuscular rupture as the magnetic resonance images were reviewed by two separate faculty Radiologists who came to the same conclusion. We also feel that our explanation is the most likely, given that there is no evidence of injury to the proximal or distal bicipital tendons, which would be expected in any sort of traumatic rupture of the biceps brachii.

Minimal motor loss would be expected secondary to the muscle tear, as the tear was longitudinal and the tendons were spared. The patient's motor deficits were more likely the result of musculocutaneous neuropathy leading to diminished neurologic input to the muscle fibers, which can explain the patient's initial profound weakness in elbow flexion. It is more difficult to determine the etiology of the patient's sensory deficits initially. He had sensory loss in the lateral forearm as well as the dorsum and palmar aspects of the first two digits and the thenar eminence. This seems to correlate with sensory loss in both median and radial nerve distributions. When the patient was re-evaluated, the sensory loss remained only in the lateral aspect of the forearm, and electrodiagnostic studies were undertaken to determine if a nerve injury could be diagnosed. Unfortunately, lateral antebrachial cutaneous sensory nerve stimulation was not technically possible on either side. However, 2+ fibrillation and 2+ positive sharp waves were seen in the right biceps brachii, indicative of active denervation. Large amplitude, long duration polyphasic motor unit action potentials were also noted in the right biceps brachii, which suggests neuropathic injury to this muscle. Unfortunately, no other muscles were tested to isolate a specific nerve injury. It is possible that the initial, more widespread anesthesia and paresthesias were due to compression of multiple nerves due to soft tissue edema. The patient was clinically noted to have soft tissue swelling throughout the upper extremity prior to our consultation, but no mention of tenseness or concern for compartment syndrome was mentioned. Once the edema had resolved, the patient continued to have sensory deficits in the specific distribution of the lateral antebrachial cutaneous nerve.

Traditionally, MRI has been the diagnostic modality of choice for detecting rupture of any portion of the biceps^{4, 6}. Recently, Authors have shown excellent accuracy in the detection of distal biceps tendon ruptures with ultrasound using an anterior viewing approach, due to the capability of detecting the hypoechogenicity of the associated hematoma⁶. Giuffre and Lisle describe the ability to detect distal biceps tear using a posterior approach⁷. Based on these factors, a single imaging technique could have diagnosed both

of this patient's conditions – thrombosis and muscle tear. There is an obvious cost-saving measure in obviating the need for MRI, as well. Unfortunately, our hospital did not have musculoskeletal ultrasonographic capability at the time that this case occurred.

Another important point in this case report is the role of re-siting peripheral intravenous catheters. Most hospitals have policies in place to rotate PIVs every 96 hours. Interestingly, a recent study did not show significance in morbidity between re-siting PIVs based on clinical indication (i.e. phlebitis or catheter failure) or "routine re-siting" every 96 hours⁸. There has been a recent trend towards replacing/re-siting PIVs only in the setting of clinical failure of the existing PIV, but this is a case in which the morbidity associated with a PIV might have occurred as a direct result of the phlebitis associated with the PIV. That is to say, re-siting the IV might have only ensured that the damage already done was not worsened.

Furthermore, there is no one medically accepted protocol for PIV insertion, care, and removal. This was demonstrated amongst a survey of 266 anesthesiologists discussing this topic in regards to operating room PIVs⁹. Another research study recommended changing PIVs only when clinical complications arose¹⁰. Yet another recommended flushing PIVs only once every 24 hours to avoid multiple flushes and manipulations of PIVs which can be cost ineffective and cause more harm with additional PIV manipulation¹¹. A study of 458 children recommended that most PIVs are kept in too long and in addition to earlier catheter changes they recommended to avoid PIVs placement in the antecubital fossa. PIV's placed in the hand had far less complications including dislodgment, occlusion, and phlebitis when compared to those in the antecubital fossa¹². A study of 3,283 patients with approximately 5,900 catheters in a secondary analysis of a randomized control trial also recommended a more distal insertion sites due to decreased incidence of occlusion, phlebitis and accidental removal and in addition to better selection criteria for appropriate PIV diameter size and insertion by an intravenous access teams or other specialists¹³. There is no one protocol for PIV care. The above studies can hopefully lend guidance to minimizing PIV complications.

In conclusion, we have described a case of a patient who suffered from a longitudinal tear of the biceps brachii with sparing of the bicipital tendons in the setting of basilic vein thrombosis, caused by PIV infiltration and basic recommendations to consider in regards to PIV complications. This can now be added to the differential diagnosis of muscle rupture, especially in patients with a history of chronic corticosteroid usage. Although we were not able to demonstrate neuropathy of the lateral antebrachial cutaneous nerve on nerve conduction study, the patient's symptoms correlate clinically with this sensory loss/impairment distribution, and are consistent with the mechanism of compression injury from edema given the path and location of the nerve. We hypothesize that compres-

sion of a portion of the radial nerve may account for the initial sensory deficits in the area of the thumb.

References

1. Lorbach O, Kieb M, Grim C, Engelhardt M. Proximal and distal rupture of the m. biceps brachii. *Orthopade*. 2010;39:1117-1122.
2. Padulo J, Oliva F, Frizziero A, Maffulli N. Muscles, Ligaments and Tendons Journal. Basic principles and recommendations in clinical and field science. *MLTJ*. 2013;4:250-252.
3. Rohen JW, Yokochi C, Lütjen-Drecoll E. Color atlas of anatomy: a photographic study of the human body. 5th ed. Baltimore, MD: Lippincott Williams & Wilkins. 2002.
4. Chew ML, Giuffre BM. Disorders of the distal biceps brachii tendon. *Radiographics*. 2005;25:1227-1237.
5. Prednisone official FDA information, side effects, uses., 2011. (Accessed at <http://www.drugs.com/pro/prednisone.html>.)
6. Weiss C, Mittelmeier M, Gruber G. Do we need MR images for diagnosing tendon ruptures of the distal biceps brachii? The value of ultrasonographic imaging. *Ultraschall Med*. 2000;21: 284-286.
7. Giuffre BM, Lisle DA. Tear of the distal biceps brachii tendon: a new method of ultrasound evaluation. *Australas Radiol*. 2005;49:404-406.
8. Rickard CM, McCann D, Munnings J, McGrail MR. Routine resite of peripheral intravenous devices every 3 days did not reduce complications compared with clinically indicated resite: a randomised controlled trial. *BMC Med*. 2010;8:53.
9. Ball RD, Henao JP, Ibinson JW, Metro DG. Peripheral catheter infiltration: anesthesia providers do not adhere to their ideas of best practice. *J Clin Anesth*. 2013(2):115-120.
10. Abolfotouh MA, Salam M, Bani-Mustafa A, White D, Balkhy HH. Prospective study of incidence and predictors of peripheral intravenous catheter-induced complications. *Ther Clin Risk Manag*. 2014;10:993-1001.
11. Schreiber S, Zanchi C, Rofani L, et al. Normal saline flushes performed once daily maintain peripheral intravenous catheter patency: a randomised controlled trial. *Arch Dis Child*. 2015.
12. Malyon L, Ullman AJ, Phillips N, et al. Peripheral intravenous catheter duration and failure in paediatric acute care: A prospective cohort study. *Emerg Med Australas*. 2014;26(6):602-608.
13. Wallis MC, McGrail M, Webster J, et al. Risk factors for peripheral intravenous catheter failure: a multivariate analysis of data from a randomized controlled trial. *Infect Control Hosp Epidemiol*. 2014;35(1):63-68.